Sternalis muscle- rare presentation in routine surgical practice

Theebanraja Ramalingam1,3, Maya Mazuwin Yahya1,2,3Siti Rahmah Bt Hashim Isa Merican1,3, Wan Zainira Wan Zain1,3 Zaidi Zakaria1,3

1Department of Surgery, School of medical Science, Hospital Universiti Sains Malaysia, Kelantan, Malaysia

2Breast cancer awareness and research unit, Hospital Universiti Sains Malaysia

3Hospital Universiti Sains Malaysia, Kelantan ,Malaysia

Abstract

During routine mastectomy dissection of an anterior chest wall mass, a unilateral appearance of the right sternalis muscle (SM) was observed. It originated from the sternal part of the right sternocleidomastoid muscle (SCM). The right SM muscle fibres travelled down inferior laterally and inserted on the ipsilateral 5th–7th ribs and the aponeurosis of the external oblique muscle. The innervation to the muscle could be traced to the 4th, 5th, and 6th anterior intercostal nerves. Awareness of the location of the sternalis will help medical doctors avoid misdiagnosis during mammography or misjudgement during breast surgery. Because of its superior attachment to the SCM, therapists need to be aware of such an anomaly.

Keywords: Sternalis muscle, Rare entity, Unilateral, Clinical significance

Introduction

The sternalis muscle is a rare variant of the anterior thoracic chest wall musculature. The sternalis muscle was first documented by Turner (1)in the 19th century and has been well reported in recent years as a variant muscle in anatomical literature(2, 3). During mastectomy of a patient a breast lump, we observed a right-sided unilateral vertical band of the sternalis muscle fibres overlying the right lateral edge of the sternum. Sternalis muscle is an accessory muscle of the anterior thoracic region. It occurs rarely in humans and not commonly encountered by clinicians and surgeon. Sternalis muscle is usually recognised unintentionally

during surgical procedures, commonly in mastectomies. In literatures this muscle is called as musculus sternalis , presternalis, sternalis muscle, sternalis brottrum, orthoracis(4, 5). This report of an incidentally detected sternalis muscle is being presented for its clinical significance in day to-day clinical practice

Case report

A 47-year-old female patient presented to the surgical outpatient department of our centre, with a right breast lump of approximately 3 cm in diameter. On evaluation she was found to have a T2N1M0 carcinoma in her right breast. After a detailed workup she was scheduled for modified radical mastectomy of the right breast. Upon performing right mastectomy, a thin ribbon like muscle was identified in the parasternal area with its fibres oriented craniocaudally, parallel to the sternum and perpendicular to the fibres of the right pectoralis major muscle (Figure 1). The muscle was thin, approximately 10 cm in length and 3 cm in breadth. Fibrofatty breast tissue was found below the muscle which was cleared during dissection. The muscle was arising from the sternum below the sternal head of the sternocleidomastoid muscle of the right side and inserted into the costal cartilages of the 5th and 6th right ribs, and its tendon was separate from the rectus abdominis muscle. The sternalis muscle was identified on perioperative CT scan of thorax, abdomen, and pelvis as well (Figure 2)

Figure 1 Right mastectomy wound

Figure 2- axial view

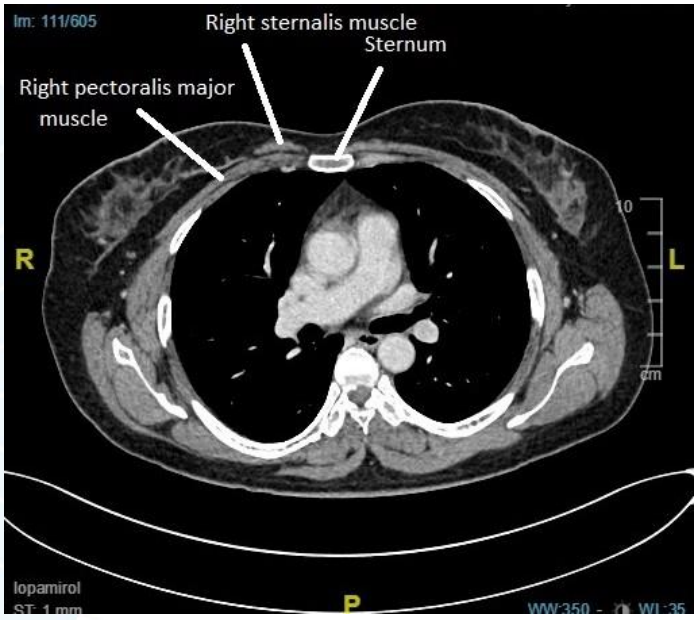

Figure 2- sagittal view

Discussion

According to the literature sternalis defined as a muscle originating from anterior thoracic fascia to pectoralis fascia(2). It originates from infraclavicular or sternal region. Its insertion could be at the rectus sheath, costal cartilage, lower ribs or external oblique aponeurosis. Commonly it is unilateral and it has equal incidence in both genders. The occurrence of sternalis muscle varies according to ethnicity(6). The highest incidence is among Asian population(11.5%)(6, 7). According to previous studies, sternalis is a part of the thorax ventral longitudinal muscle column arising from the ventral lips of hypomere which is represented by rectus abdominis muscle in abdomen and strap muscles in the neck(8). The nerve supply of the sternalis muscle is from internal or external thoracic or pectoral nerve in 55% of cases, intercostal nerves in 43% of cases, and both in 2% of cases(1, 5). Intercostal nerves do not supply the sternalis muscle despite piercing through it(9). Arterial supply of sternalis muscle is from perforating branches of internal thoracic artery. Sternalis muscle plays accessory role in lower chest wall elevation(2, 10). The contraction of this muscle helps to elevate the lower part of the thorax

Clinical significance

Sternalis muscle has been well explained and described in the literature. Despite that, knowledge among physicians, surgeons, oncologists, and radiologist is deficient in view of rarity and unfamiliarity to the sternalis muscle(11). This is because in most of the standard anatomical textbooks it is not adequately mentioned.However lately there is renewed interest about this muscle among clinicians because of the following reasons:

1. During routine mammography sternalis muscles can be mistaken for a tumour in the craniocaudal view during initial investigation or as a recurrence during follow-up in the postoperative period. Presence of this muscle can be confirmed by computed tomography (CT) or magnetic resonance imaging (MRI) and craniocaudal view in mammography(1, 12)

2. During radiotherapy the depth at which internal thoracic nodes are irradiated may vary in presence of this muscle(13)

3. Presence of sternalis muscle can cause changes in electrical activities during electrocardiography(11)

4. During oncological procedures it is important to excise this muscle as part of breast tissue lies deep in it (11, 14)

5. If detected preoperatively sternalis muscle can be used in reconstructive surgery(1)

Conclusion

In view of latest advancement in medical science with new diagnostic and therapeutic modalities, sternalis muscle could be identified more routinely in our medical practice. It also could provide a diagnostic dilemma which could be rectified with imaging like MRI or CT. If detected preoperatively it can be used in various reconstructive procedures during surgery. When detected intraoperatively during mastectomy for carcinoma of the breast, it should ideally be removed for complete clearance of the breast tissue.

Consent

Written and informed consent was taken from the patient for publication of this case report.

Conflict of Interests

The authors declare that there is no conflict of interests regarding the publication of this paper

Reference

1. Turner WJJoa, physiology. On the musculus sternalis. 1867;1(2):246.

2. Raikos A, Paraskevas GK, Tzika M, Faustmann P, Triaridis S, Kordali P, et al. Sternalis muscle: an underestimated anterior chest wall anatomical variant. 2011;6(1):1-4.

3. Sarıkçıoglu L, Demirel BM, Oğuz N, Uçar YJA. Three sternalis muscles associated with abnormal attachments of the pectoralis major muscle. 2008;2(1).

4. JENG H, SU S-JJTJoA. The sternalis muscle: an uncommon anatomical variant among Taiwanese. 1998;193(2):287-8.

5. O'neill M, Folan-Curran JJJoa. Case report: bilateral sternalis muscles with a bilateral pectoralis major anomaly. 1998;193(2):289-92.

6. Bharathi D, Sarala H, Padmalatha NJIJoLSR. Balakrishna,“Morphology of rectus sternalis: a cadaveric study,”. 2014;2(4):65-7.

7. Jelev L, Georgiev G, Surchev LJJoa. The sternalis muscle in the Bulgarian population: classification of sternales. 2001;199(3):359-63.

8. Sadler TJNY. Langman's Medical Embryology, Lippincott Williams & Wilkins. 2004.

9. KIDA MY, KUDOH HJOfaj. Innervation of the sternalis muscle accompanied by congenital partial absence of the pectoralis major muscle. 1991;67(6):449-55.

10. Bhat KM, Potu BK, Gowda SJCJ. Sternalis muscle revisted in South Indian male cadaver: a case report. 2009;2(1):6318.

11. Cherian S, Gandhalam AJOA. Rectus sternalis muscle: An anatomical variant of anterior chest wall. 2014;2(2):16.

12. Gnanasundaram V, Subramanian A, Rajendran H, Thotakura BJIJoA, Embryology. Sternalis "mystery" muscle and its clinical implications. 2011;116(3):139-43.

13. PREETI T, HARSHA B, UJWAL G, ETI S, SUNITA B, MANJIRI C, et al. The Bilateral Sternalis: An Uncommon Anatomical Variant. 2012;6(5).

14. Kabay B, Akdogan I, Ozdemir B, Adiguzel EJFm. The left sternalis muscle variation detected during mastectomy. 2005;64(4):338-40.